

# The Hip Joint: Arthroscopic Procedures and Postoperative Rehabilitation

Keelan R. Enseki, PT, MS, ATC, SCS, CSCS<sup>1</sup>

RobRoy L. Martin, PT, PhD, CSCS<sup>2</sup>

Peter Draovitch, PT, MS, ATC<sup>3</sup>

Bryan T. Kelly, MD<sup>4</sup>

Marc J. Philippon, MD<sup>5</sup>

Mara L. Schenker, BS<sup>6</sup>

Recent technological improvements have resulted in a greater number of surgical options available for individuals with hip joint pathology. These options are particularly pertinent to the relatively younger and more active population. The diagnosis and treatment of acetabular labral tears have become topics of particular interest. Improvements in diagnostic capability and surgical technology have resulted in an increased number of arthroscopic procedures being performed to address acetabular labral tears and associated pathology. Associated conditions include capsular laxity, femoral-acetabular impingement, and chondral lesions. Arthroscopic techniques include labral tear resection, labral repair, capsular modification, osteoplasty, and microfracture procedures. Postoperative rehabilitation following arthroscopic procedures of the hip joint carries particular concerns regarding range of motion, weight-bearing precautions, and initiation of strength activities. Postoperative rehabilitation protocols that have been typically used for surgeries such as total hip arthroplasty are often not sufficient for the population of patients undergoing arthroscopic procedures of the hip joint. Postoperative rehabilitation should be based upon the principles of tissue healing as well as individual patient characteristics. As arthroscopic procedures to address acetabular labral tears and associated pathology evolve, physical therapists have the opportunity to play a significant role through the development of corresponding rehabilitation protocols. *J Orthop Sports Phys Ther* 2006;36(7):516-525. doi:10.2519/jospt.2006.2138

**Key Words:** clinical research, hip, labrum, lower extremity

**T**he advancement of diagnostic procedures along with the development of improved arthroscopic instrumentation and techniques has broadened the range of treatment options for individuals with hip joint pathology. Recently, the surgical treatment of acetabular labral tears has been of particular interest. Treatment options have evolved from simple resection of the torn tissue to more advanced labral repair procedures.

Correction of other abnormalities of the joint associated with, or contributing to, the underlying cause of a labral tear, including capsular laxity, femoral-acetabular impingement (FAI), and chondral lesions, through recent advances can now also be performed through arthroscopic procedures.

Arthroscopic procedures have evolved in the last decade to address labral tears and associated pathologies and are typically performed on young, active individuals. As a result, traditional hip rehabilitation protocols have been adapted to meet the demands of this patient population. Rehabilitation for individuals having a total hip arthroplasty (THA) or surgical procedures to address fractures have typically focused on gait training, weight-bearing status, range of motion (ROM) precautions, and activity modification, with a goal of returning to specific activities of daily living, but most often not strenuous labor or competitive sport.<sup>9,22,59</sup> The active population of patients undergoing hip arthroscopy raise additional concerns regarding increased joint load demands, proprioception, muscle imbalances, lumbopelvic stability, strenuous occupation demands, and possibly return to competition. As surgeries to cor-

<sup>1</sup> Orthopaedic Physical Therapy Residency Program Director, Centers for Rehab Services, University of Pittsburgh Center for Sports Medicine, Department of Physical Therapy, University of Pittsburgh School of Health and Rehabilitation Sciences, Pittsburgh, PA.

<sup>2</sup> Assistant Professor, Department of Physical Therapy, Duquesne University, Pittsburgh, PA.

<sup>3</sup> Physical Therapist, Centers for Rehab Services, University of Pittsburgh Center for Sports Medicine, Pittsburgh, PA.

<sup>4</sup> Assistant Professor of Orthopaedic Surgery, Hospital for Special Surgery, New York-Presbyterian Hospital, Weill Medical College of Cornell University, New York, NY.

<sup>5</sup> Orthopaedic Surgeon, Steadman-Hawkins Clinic, Steadman-Hawkins Research Foundation, Vail, CO.

<sup>6</sup> Research Assistant, Steadman-Hawkins Research Foundation, Vail, CO.

There is no financial affiliation or involvement of any commercial organization that has a direct financial interest in any matter included in this manuscript.

Address correspondence to Keelan R. Enseki, Centers for Rehab Services, UPMC Sports Medicine Complex, 3200 South Water Street, Pittsburgh, PA 15203. E-mail: [ensekikr@upmc.edu](mailto:ensekikr@upmc.edu)

rect disorders of the acetabular labrum and associated pathology are performed more often, postoperative protocols must reflect the evolution of these procedures and the demands of the patient population.

## Indications

Potential candidates for arthroscopic procedures to address acetabular labral tears and associated pathology should be identified through clinical and diagnostic testing. Initially, an attempt should be made to determine if the cause of symptoms is extra-articular, intra-articular, or from a structure other than the hip joint (referred pain). The examination includes the assessment of ROM, strength, and special tests for the hip joint, as well as lower-quarter-screening components to rule out lumbosacral spine or knee joint involvement. Identifying a labral tear through clinical examination may be difficult and, therefore, diagnostic imaging may be necessary. Imaging modalities are most effective when their selection is based upon a complete history and physical examination.<sup>3</sup> Plain-film radiographs may include supine anterior-posterior pelvis, frog-lateral, cross-table lateral, and/or false-profile views. Magnetic resonance imaging (MRI) may be performed to evaluate soft tissue injuries, including chondral and labral pathologies.<sup>37</sup> Gadolinium-enhanced magnetic resonance arthrography may also be used to image labral and chondral pathology in the hip. If history, physical examination, and medical imaging analysis lead to suspicion of a labral tear, an attempt should also be made to determine the presence of associated joint laxity, FAI, or joint degeneration.

After clinical and diagnostic evidence is evaluated, candidacy for arthroscopic surgery is determined. Individuals who suffer from persistent hip pain that has not responded to conservative intervention provided for longer than 4 weeks and who show signs of intra-articular hip pathology are considered to be potential candidates for hip arthroscopy.<sup>29</sup> Contraindications for hip arthroscopy include hip fusion, cellulitis, severe acetabular dysplasia, femoral neck stress fracture, stable avascular necrosis, inability or unwillingness to comply with rehabilitation protocols, arthrofibrosis, and advanced joint degeneration. An association between the presence of advanced cartilage degeneration and poor outcomes following hip arthroscopy has been suggested.<sup>36</sup> Individuals in this category may be better suited for a trial of conservative treatment, with a focus on manual therapy.<sup>25</sup> If satisfactory results are still not achieved, the patient may be a candidate for a THA procedure.

## Arthroscopic Examination

Arthroscopy of the hip may be performed with the patient in the supine or lateral position.<sup>7,21</sup> A distrac-

tion force is applied under fluoroscopic evaluation, along with gentle traction to the contralateral limb to provide a counterforce. Typically 11.3 to 22.6 kg of force is required to create the minimum 8 to 10 mm of hip joint distraction necessary to perform arthroscopy and reduce the risk of iatrogenic chondral or labral injury. Flexible instrumentation now allows access to the deeply recessed joint structures for arthroscopic intervention. Though numerous variations have been described, 3 basic portals are most commonly utilized: anterolateral, anterior, and posterolateral.

Systematic arthroscopic examination of the hip can be performed through 2 portals: anterolateral and anterior.<sup>28</sup> The anterolateral portal is placed approximately 1 to 2 cm superior and 1 to 2 cm anterior to the anterosuperior portion of the greater trochanter. The anterolateral portal allows examination of numerous structures within the joint, including the anterior and superior labrum, the anterior femoral head and neck, the cotyloid fossa, and ligamentum teres. The psoas tendon, also visible through this portal, most commonly lies medially to a thin barrier of capsular tissue and can be palpated with a probe. In approximately 20% of the population, the psoas tendon and/or bursa may be intra-articular.<sup>43</sup>

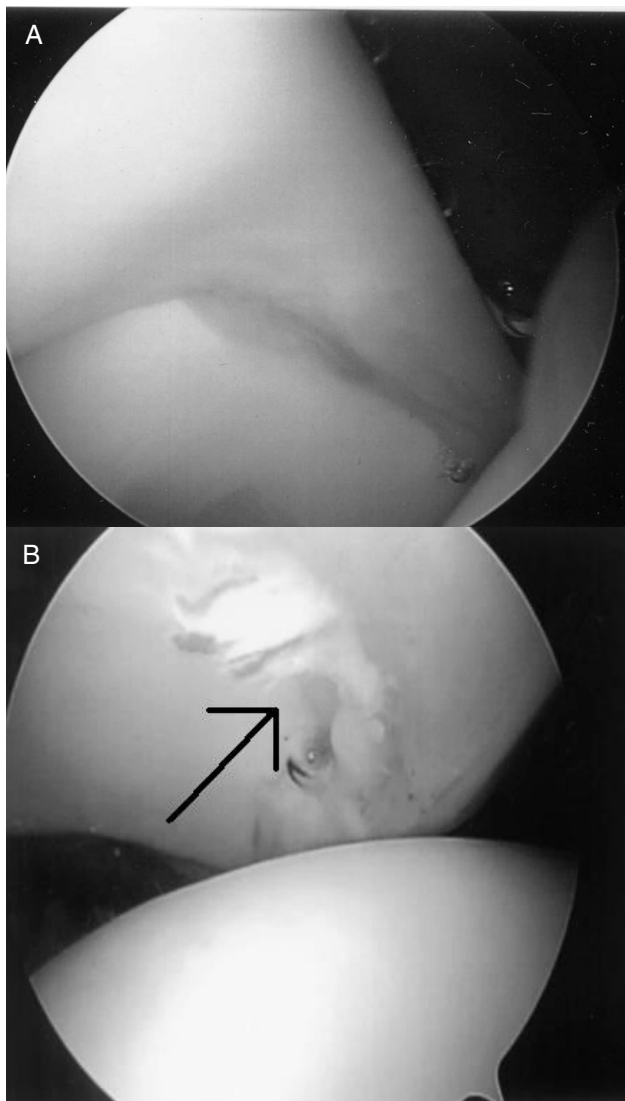
The anterior portal is placed directly inferior to the anterior superior iliac spine at the horizontal intersection of the anterolateral portal. It allows a detailed view of structures, including the anterior acetabular rim, posterior labrum, ligamentum teres, and cotyloid fossa. Placement of this portal requires precise knowledge of the anatomy of the region to avoid potential damage to numerous neurovascular structures, including the lateral femoral cutaneous nerve, lateral femoral circumflex artery, and femoral neurovascular bundles.<sup>12</sup>

The third portal (posterolateral) can be placed 2 to 3 cm posterior to the tip of the greater trochanter at the same level as the anterolateral portal. The sciatic nerve needs to be carefully avoided during the placement of this portal.<sup>29</sup> Visualization of the posterior aspect of the femoral head, the posterior labrum, posterior capsule, and the inferior edge of the ischiofemoral ligament is possible from this portal.<sup>12</sup> The posterolateral portal can also be useful for the removal of loose bodies.

Other portals may be established as needed for visualization and treatment of otherwise inaccessible regions of the joint.

## Labral Resection

Recent advances in arthroscopic technology have resulted in an increased number of treatment options for individuals with labral pathology of the hip. The choice of surgical technique can vary depending on the type, size, location, and degenerative condition of the labral tear. As with the debridement of a meniscal



**FIGURE 1.** (A) normal acetabular labrum under arthroscopic examination; (B) frayed acetabular labrum.

tear in the knee, it is believed that mechanical symptoms and immediate pain will be relieved by removing the unstable portion of the labrum. Once a labral tear has been identified, resection of the unhealthy labral tissue is performed. An attempt is made to spare as much stable tissue as possible to preserve the mechanical integrity of the joint (Figure 1).<sup>15-16</sup>

A number of studies have reported favorable outcomes following debridement of a labral tear (Table 1).<sup>13,17,24,31,42,47,51</sup> Potter et al<sup>47</sup> recently performed a study examining the association of Short Form-36 and disability status with outcomes of arthroscopic acetabular debridement. Twenty-eight months postsurgery, they found arthroscopic debridement yielded good or excellent results on the Modified Harris Hip Score (MHHS) in 68% of patients, with 84% being very or somewhat satisfied, when patients undergoing military disability evaluations were excluded. Farjo et al<sup>13</sup> found that 71% of patients

undergoing arthroscopic labral resection had good to excellent results at 1-year follow-up, if they did not have significant preoperative hip arthritis. Byrd and Jones<sup>8</sup> performed a prospective analysis of patients undergoing arthroscopic procedures for tears of the acetabular labrum. They reported a significant improvement of symptoms in patients on the MHHS during a 2-year follow-up after arthroscopic labrum resection. A number of the studies presented in Table 1 are case series. Therefore, these results should be considered, while acknowledging that case series have been noted to overestimate the therapeutic effects of interventions.<sup>53</sup>

### Labral Repair

The ability to perform labral repairs has recently been reported.<sup>28,46</sup> Individuals with a labrum that is partially detached from the bony acetabulum or who have intrasubstance tears are considered candidates for repair. A repair is chosen over resection to avoid significant disruption of joint mechanics.<sup>15-16</sup> In the case of detachment, a bioabsorbable suture anchor is placed on the rim of the acetabulum. After the anchor is established, suture material is passed through the labrum twice to create a vertical mattress suture. When an intrasubstance split in the labrum is observed, a bioabsorbable suture is passed around the split, utilizing a suture lasso or similar instrumentation. Once the suture is tied, the split labral tissue is reapproximated. Repairs of the acetabular labrum share common concerns with meniscal repairs for the knee regarding vascularity and healing potential. McCarthy et al<sup>35</sup> found limited vascularization occurring in the labrum-capsular sulcus and the junction between the acetabulum and fibrocartilagenous labrum. Flap or frayed tears, as well as tears with considerable degeneration, are not considered to be repairable. These tears should be debrided, leaving as much healthy tissue as possible. Early results for arthroscopic labral repair procedures appear to be favorable. Leunig<sup>33</sup> reported preliminary data comparing labral resection and repair using an open procedure. They showed significantly better subjective outcomes in patients undergoing repair as compared to resection.

### Osteoplasty and Rim Trimming

FAI has been recognized as a cause of acetabular labral tears and chondral injuries that may eventually lead to joint degeneration.<sup>4,20,39,57</sup> A decreased offset of the femoral head-neck junction secondary to abnormalities of the femoral head (cam impingement) or acetabulum (pincer impingement), or a combination cam and pincer impingement, has been observed.<sup>20,26,41,48</sup> The decreased clearance between the femoral head-neck region and the acetabulum

**TABLE 1.** Reported outcomes and average follow-up after procedures of the hip joint intended to address acetabular labral tears and/or femoral-acetabular impingement.

Study Author(s)	Study Description/Subjects (n)	Average Length of Follow-up	Outcomes
Beck et al <sup>5</sup>	Retrospective case series of patients undergoing open bony resection to address femoral-acetabular impingement (n = 19)	4.0-5.2 y	13 hips rated as good to excellent on the Merle d'Aubigné and Postel Hip Score; 5 had subsequent total hip arthroplasty
Byrd and Jones <sup>8</sup>	Prospective study of patients undergoing hip arthroscopy (n = 35)	2 y	Significant symptom improvement on the Modified Harris Hip Score (MHHS); best results occurring for labral tears and removal of loose bodies
Farjo et al <sup>13</sup>	Retrospective case series of patients who had hip arthroscopy performed for debridement of a labral tear (n = 28)	13-100 mo	71% of patients without preoperative arthritic findings had good to excellent results on a numeric self-report scoring system compared to 21% for those with arthritis
Hase and Ueo <sup>24</sup>	Retrospective case report review of patients diagnosed with labral tears (n = 10)	15-68 mo	8 patients had arthroscopic resection of the torn labrum and were symptom free at follow-up; 2 patients did not recover with conservative treatment
Murphy et al <sup>38</sup>	Prospective study of patients undergoing open bony debridement as treatment to address femoral-acetabular impingement (n = 23)	2-12 y	15 hips functioning well on the Merle d'Aubigné and Postel Hip Score without further intervention; 7 converted to total hip arthroplasty; no subjects developed osteonecrosis
Oleary et al <sup>42</sup>	Retrospective study comparing results of arthroscopy of the hip for osteonecrosis compared to other diagnoses (n = 86) (43% osteonecrosis, 20% labral injury, 10% osteoarthritis, 10% Legg-Calvé-Perthes disease, 10% loose bodies)	Average, 30 mo; minimum, 20 mo	91% of patients having arthroscopy for labral tears reported significant improvement through self report, compared to 40% for osteonecrosis, and 44% for degenerative joint disease
Potter et al <sup>47</sup>	Retrospective case series of patients undergoing arthroscopic acetabular labrum debridement (n = 40)	13-55 mo	Patient self-reported satisfaction rates were 70% overall; 50% for those undergoing military disability evaluations versus 84% for those who were not
Santori and Villar <sup>51</sup>	Case series review of patients undergoing arthroscopy to address acetabular labral tears (n = 76)	24-61 mo	Of the 58 cases remaining at follow-up, 67.3% reported being pleased with the results of their operation (mean MHHS, 89.8); 32.7% were not satisfied (mean MHHS, 49.5)

results in impingement between the bony structures, particularly in hip positions of flexion and internal rotation. Labral and chondral injuries have been shown to be associated with FAI. An open surgical dislocation approach to the decompression of FAI has been described.<sup>19,32</sup> The open technique has produced favorable outcomes in individuals who do not

have advanced degeneration of the joint (Table 1).<sup>4,5,38</sup> It should be noted that the Merle d'Aubigné and Postel Hip Score, utilized as outcome measures in a number of studies, was originally designed to measure pain, mobility, and ambulation characteristics in individuals following THA. Therefore, it may overestimate the functional status of individuals who



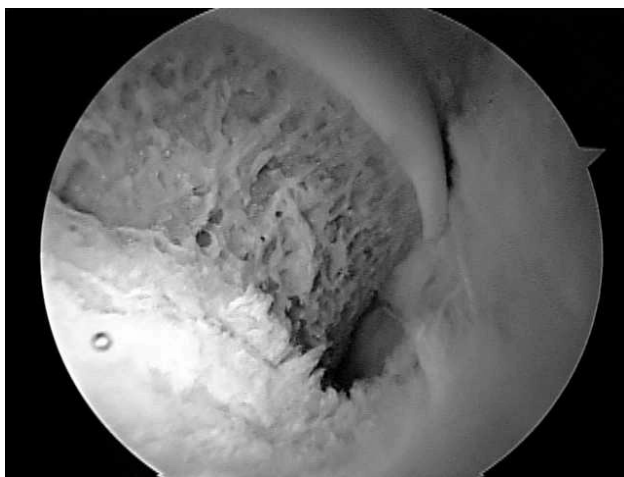
are typically more active in comparison to this population.

Current advances now allow for osteoplasty of cam impingement and rim trimming of pincer impingement to be performed through arthroscopy.<sup>46,45</sup> This method avoids surgical dislocation and thus reduces the risk of developing avascular necrosis, infection, or nonunion of the greater trochanter. In the osteoplasty technique, the femoral head-neck offset is improved by removing any significant nonspherical portion of the femoral head (Figure 2). The rim-trimming technique allows resection of the anterior acetabular overcoverage.<sup>5</sup> Resection or repair of the damaged labrum can be performed during the same procedure. Outcome studies comparing arthroscopic osteoplasty to the conventional open dislocation procedures do not exist at this time.

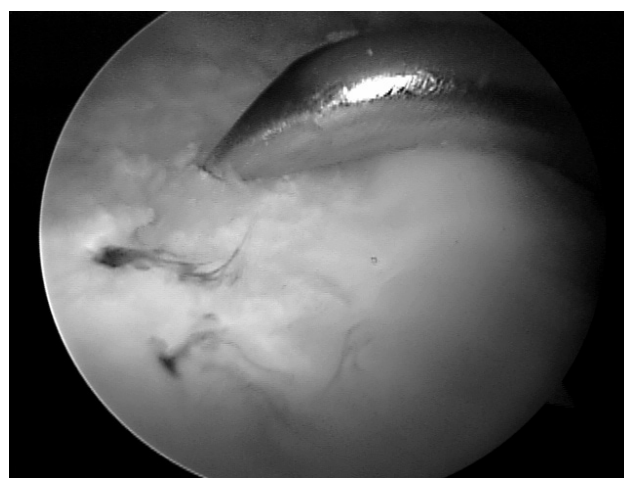
### Capsular Modification

As with FAI, capsular laxity has been associated with labral lesions. Injury to the labrum or attenuation of the capsuloligamentous structures can result in a disturbance of the buffer mechanism of hip stability. This may create a disproportionate load distribution and resulting injury to both structures. Rotational instability, particularly in the athletic population, is associated with sports involving axial loading and external rotation, and is likely related to elongation of the iliofemoral ligament. Procedures including thermal capsulorrhaphy or plication may be performed to address capsular laxity.<sup>52</sup> In a small study (n = 11 hips) of professional athletes who underwent labral resection and capsular thermal modification of the hip, 81% returned to preinjury level of competition with minimal or no pain.<sup>44</sup>

Recently, arthroscopic plication of the iliofemoral ligament has been performed on patients demonstrating significant redundancy and capsular laxity.<sup>29</sup> During this procedure, a bioabsorbable suture is



**FIGURE 2.** Postosteoplasty view of the femoral head-neck junction.



**FIGURE 3.** Microfracture procedure for chondral lesion of the acetabulum: a surgical awl is used to create lesions in the subchondral bone.

tensioned at the margin between the iliofemoral and ischiofemoral ligaments. Plication of the iliofemoral ligament and repair of the labrum to address recurrent anterior instability of the hip joint can be compared to a Bankart procedure performed for shoulder instability and glenoid labrum compromise. Data on long-term effectiveness of plication procedures for the hip joint are needed.

### Microfracture Procedures

McCarthy et al<sup>36</sup> observed that 74% of patients with a frayed or torn labrum also had chondral lesions. Arthroscopic observation suggested an association between progression of labral lesions and progression of anterior articular cartilage lesions of the acetabulum.<sup>34</sup> Though not completely understood, cartilage damage may play a detrimental role in the outcomes of patients undergoing arthroscopic procedures of the hip joint.<sup>36,39</sup> Often found in conjunction with labral tears, medium-sized, full-thickness articular lesions of the femoral head and acetabulum can be addressed through arthroscopic microfracture procedures.<sup>29</sup> Microfractures are created in the subchondral bone in an attempt to facilitate the growth of hyaline-like fibrocartilage (Figure 3). Though there are no current outcome studies regarding patients undergoing microfracture procedures for the hip joint, functional improvement and decreased pain have been reported with the use of the microfracture techniques in the knee.<sup>56</sup> In the hip, the microfracture technique is currently recommended for well-contained chondral defects in the acetabulum and the femoral head up to 400 mm<sup>2</sup>. The authors make this recommendation based upon the reported outcomes following microfracture procedures of the knee.<sup>56</sup>

## Complications

The reported complication rate associated with arthroscopy of the hip joint ranges from 1.3% to 1.6%.<sup>6,11,23</sup> In comparison, complication rates for arthroscopic procedures of the knee and shoulder have been reported in the ranges of 1.29% to 8.2%<sup>54,55</sup> and 5.8% to 9.5%,<sup>58</sup> respectively. Potential complications are most often related to joint distraction, joint entry, and fluid management.<sup>11,40,50</sup> Pudendal, sciatic, and femoral neuropraxias have been reported.<sup>11,18,23,50</sup> The vast majority of these neuropraxias are transient in nature,<sup>11,40</sup> and may be related to the total time spent in traction.<sup>50</sup> Less common complications that have been reported include instrument breakage, heterotopic ossification, reflex sympathetic dystrophy, labia majora hematoma, trochanteric bursitis, and infection.<sup>6,11,18,23,30</sup>

## Preoperative Rehabilitation

Griffin et al<sup>22</sup> noted the importance of preoperative rehabilitation in patients undergoing arthroscopic hip procedures. Goals in common with preoperative therapy for many other orthopaedic surgeries include maximizing ROM, strength, and endurance, without exacerbating the patient's symptoms. During this time, patients who may not be compliant with the prescribed therapeutic protocol may also be identified. These individuals would not typically be considered good candidates for surgery. Preoperative therapy also gives the therapist an opportunity to explain multiple aspects of the postoperative rehabilitation process, including weight-bearing restrictions, as well as duration and frequency of therapy.

## Postoperative Rehabilitation

It should be emphasized that arthroscopic procedures of the hip joint have only become more popular in recent times and continue to rapidly evolve. At this time minimal evidence exists regarding postoperative rehabilitation for these procedures. The guidelines suggested in this commentary are highly based on the authors' combined clinical experience gained from working with more than 500 patients undergoing these procedures. These guidelines will hopefully provide a foundation from which clinical studies can be designed.

Though the postoperative rehabilitation program varies depending on the nature of procedure and patient characteristics, general recommendations can be made. In our experience, 10 to 12 weeks of supervised therapy is sufficient for an individual undergoing arthroscopic resection or repair of the labrum as well as any of the previously mentioned adjunct procedures. The immediate goal of therapy is to control postoperative inflammation through

prescribed nonsteroidal anti-inflammatory drugs (NSAIDs), ice, and compression. The authors utilize a motorized cuff system (Cryo/Cuff AutoChill System; Aircast, Summit, NJ) to continuously deliver compression with water kept cold in a reservoir of ice. The progression of weight-bearing, ROM, and strengthening activities is dictated by current knowledge of the tissue-healing response for each specific surgery (Table 2).

Limited ROM activities are initiated early after surgery. Patients are issued a brace (Post-op Hip Brace; Bledsoe, Grand Prairie, TX) to protect the joint and limit ROM, particularly hip abduction and rotation. The brace is worn during ambulation for approximately 10 postoperative days. The brace is set at a neutral position to approximately 80° of flexion in the sagittal plane. Rotation precaution boots (KAF positioning kit; Bledsoe, Grand Prairie, TX) are worn at night to prevent the hips from falling into external rotation during sleep. External rotation places the anterior capsuloligamentous structures under increased tension. Avoiding prolonged periods of increased tension is of particular importance, especially for individuals undergoing capsular modification procedures. These individuals may be directed to utilize the immobilization system for up to 4 weeks postsurgery. A continuous passive motion (CPM) device is prescribed to be used for up to 8 hours per day for 2 to 4 weeks in all patients undergoing hip arthroscopy to reduce the risk of developing postoperative adhesions and to encourage early postoperative healing. This is the same CPM device utilized after surgical procedures of the knee joint. The initial setting provides movement between 30° and 70° of flexion. This can be increased as tolerated, with an eventual goal of movement between full extension and maximally tolerated flexion.

Hip ROM activities are introduced based on the healing properties of the involved tissues (comparative healing rates of bone, labral tissue, capsuloligamentous structures, and cartilage). The factors to be considered are the pliability potential versus the risk of tissue damage.<sup>10</sup> ROM activities can be initiated in a fairly aggressive manner for individuals undergoing isolated resection or repair of the labrum. In the majority of cases, a patient will utilize a stationary bike without resistance the day of surgery. Excessive hip flexion or abduction should be avoided to prevent discomfort often noted to occur during these ranges of motion. In the authors' experience, excessive flexion or abduction early in the rehabilitation process can result in the patient reporting a well-defined "pinching" sensation that is often followed by a period of general soreness in the anterior thigh or lateral hip region. Full passive ROM, as dictated by patient tolerance, is typically allowed at 14 days after surgery. If an anterior

capsular modification procedure was also performed, hip external rotation and extension beyond 10° should be limited for 21 to 28 days to protect the anterior portion of the capsule. The need for protecting the anterior capsuloligamentous structures is comparable to the postoperative scenario following anterior capsular reconstruction of the shoulder.<sup>27</sup> Gentle, repetitive hip internal rotation ROM exercise is stressed early in the rehabilitation process to prevent adhesions of the joint capsule and subsequent loss of motion. In the authors' experience, most patients can tolerate stretching of all muscles that cross the hip joint approximately 28 days after surgery.

Weight-bearing considerations are dependent on the area of the lesion (weight bearing versus non-weight-bearing region), nature of the procedure per-

formed, and if other procedures were performed involving the articular cartilage or bony structures. Most patients are instructed to use crutches, allowing approximately 9.1 kg of flat-foot weight bearing. If a microfracture or osteoplasty procedure is performed, partial weight-bearing status is usually preferred over complete non-weight bearing for the hip joint. This demonstrates an application of Wolff's Law; the goal being application of appropriate mechanical stress, optimizing bone formation to manage compressive loads.<sup>2</sup> A partial weight-bearing status also decreases the load placed upon the upper extremities during ambulation, compared to a non-weight-bearing status. This is particularly relevant in the relatively active population who may undergo arthroscopic surgical procedures of the hip joint. This group of patients will likely desire a relatively higher level of mobility

**TABLE 2.** Rehabilitation guidelines after selected arthroscopic procedures of the hip joint.

Surgical Procedure	Rehabilitation Concerns	Weight-Bearing Precautions	Range-of-Motion (ROM) Precautions	Strength Issues
Labral resection	Avoiding initiation of joint inflammation	Partial weight bearing for 10-14 d	Avoid excessive early flexion and abduction to prevent inflammation of affected tissue; full passive range of motion (PROM) by 2 wk	Gentle isometrics on day 2; active range of motion (AROM) at 2 wk; weight-bearing progressive resisted exercises (PREs) as tolerated after full weight bearing
Labral repair	Avoiding initiation of joint inflammation	Partial weight bearing for 10-28 d	Avoid excessive early flexion and abduction to prevent inflammation of affected tissue; full PROM by 2 wk	Gentle isometrics on day 2; AROM at 2 wk; weight-bearing PREs as tolerated after full weight bearing
Osteoplasty/rim trimming procedure	Avoid excessive compressive and tensile forces to femoral neck and head-neck junction; protect exposed bone	Partial weight bearing (approximately 9.1 kg) for 4-6 wk	Avoid excessive early flexion and abduction to prevent inflammation of affected tissue; full PROM by 2 wk	Gentle isometrics on day 2; AROM at 2 wk; caution with sagittal plane straight leg raise secondary to increased compressive forces; gentle weight bearing PREs by 4-6 wk
Capsular modification: thermal assisted, plication	Avoid excessive tension of affected capsular tissue (usually anterior region); avoid capsular inflammation	Partial weight bearing for 10-14 d	Avoid excessive early flexion and abduction; avoid forced external rotation and extension for 3-4 wk to protect anterior capsule; progress external rotation and extension after 3 wk; full PROM allowed by 4 wk	Gentle isometrics on day 2; limited AROM at 3 wk; weight-bearing PREs as tolerated after full weight bearing
Microfracture	Avoid reinitiation of inflammatory response and protect early fibrocartilage formation by limiting early compression and shear forces	Partial weight bearing (approximately 9.1 kg) for 4-6 wk	Avoid excessive early flexion and abduction to prevent inflammation of affected tissue; full PROM by 2 wk	Gentle isometrics on day 2; AROM at 2 weeks; caution with sagittal plane straight leg raise secondary to increased compressive forces; gentle weight-bearing PREs by 4-6 wk

\* For combined procedures the most conservative guidelines for each aspect of rehabilitation are observed.



and typically be ambulating greater average distances compared to individuals receiving THA procedures. A partial weight-bearing status allows application of a controlled progressive stimulus for healing, while promoting a relatively normal gait pattern.

An individual undergoing an isolated labral resection or repair typically utilizes crutches for 10 to 28 days before progressing to weight bearing as tolerated. Individuals undergoing repair procedures may be required to maintain partial weight bearing for the longer period to protect the repaired tissue and promote healing. If a patient also has a microfracture procedure or osteoplasty procedure performed, the weight-bearing progression may be prolonged for 28 to 42 days. Primary concerns with the microfracture procedure are avoiding reinitiation of the inflammatory process and protection of the forming fibrocartilage. Alford and Cole<sup>1</sup> noted the importance of patient compliance to rehabilitation recommendations following microfracture to the articular surfaces of the knee joint. They recommended non-weight bearing for 6 weeks for procedures performed on the femoral condyle or tibial plateau. For the reasons previously discussed, modified partial weight-bearing recommendations have been suggested for individuals undergoing microfracture procedures of the hip joint. In the case of an osteoplasty or rim-trimming procedure, avoiding excessive compressive or tensile forces at the femoral head-neck junction or acetabulum is a priority. The transient compromise of bony integrity that occurs with an osteoplasty procedure creates a concern for the development of femoral neck fractures during the early recovery period. The authors have found aquatic ambulation to be useful for developing gait symmetry and attempting to create an environment of optimal joint loading for patients undergoing any of the discussed procedures.

Gentle resisted exercises can be initiated the day after surgery. Such activities include isometric exercises performed in a neutral position focusing on extension, abduction, and adduction. In addition, quadriceps isometrics, and gentle lumbopelvic stabilization activities may be initiated. Active ROM is usually initiated 14 days after surgery. A particular focus is placed on strengthening the gluteus medius muscle. For individuals who had a partial release of the iliopsoas tendon, straight leg raises in the sagittal plane are not allowed for at least 28 days. In the authors' experience, early initiation of sagittal plane straight leg raise exercise is often associated with an increased inflammatory response and may be related to the development of postoperative hip flexor tendinitis. It has been noted that the hip joint experiences a force greater than several times an individual's body weight during a straight leg raise maneuver.<sup>22,49</sup> Weight-bearing progressive resistance activities (PREs) are introduced when appropriate.

Emphasis is placed on eliminating substitution patterns and progressing activities into specific functional movement patterns. Lumbopelvic stabilization activities are progressed in parallel to PREs of the hip joint. Due to the proximity of the hip joint to the lumbopelvic complex, the importance of trunk stability has been noted.<sup>3</sup> The authors suggest a useful analogy may be made between the need for lumbopelvic stabilization after hip surgery and scapular stabilization after surgical procedures of the shoulder.

Balance and functional activities are initiated as allowed by weight-bearing precautions and patients' symptomatic presentation. During balance activities, particular attention is directed towards proper recruitment of the gluteus medius muscle group, as well as continued incorporation of the more proximal lumbopelvic stabilization musculature. Activities challenging the patient in all planes of motion should be utilized. As previously mentioned, rotational instability is a preoperative finding in a number of patients with labral and capsular compromise of the hip joint. For these individuals, activities focusing on re-establishing dynamic rotational stability and motor control should be emphasized.

The time for return to function varies depending on the extent of the surgical procedure and the demand of the activities in which the patient wishes to participate. Individual morphological characteristics may also play a role in the amount of time required to return to desired activities. In the case of an isolated procedure for the labrum, jogging may be initiated as early as 8 to 10 weeks if symptoms permit. If a microfracture or FAI procedure was also performed, this time period will be extended significantly. A return to manual labor activities can be expected in 10 to 24 weeks, depending on the complexity of the case. A select few athletes undergoing resection of a small labral tear have returned to sport activities as soon as 8 weeks postsurgery. Typically, athletes can return to a competitive environment in 10 to 32 weeks. The extended time range exists to account for those individuals undergoing complex procedures that involve the articular cartilage or bony components. In rare cases, when the postoperative integrity of the joint is questionable, it may be recommended that an athlete change the training regimen or even consider refraining from specific activities. Early establishment of realistic patient goals in relation to known joint integrity will help to minimize disappointment and frustration for both the patient and therapist alike.

## CONCLUSION

The improvement of diagnostic technology and surgical technique has resulted in an expansion of the options available to individuals suffering from pathological conditions of the hip joint. There has



been a particular interest in the detection and surgical treatment of acetabular labral tears and associated lesions. Surgical procedures include labral resection, labral repair, capsular modification, osteoplasty, rim trimming, and microfracture. The common goal remains to decrease patient symptoms, improve functional outcomes, and restore long-term mechanical integrity of the joint. Initial results from a number of these procedures appear promising. However, continued outcome studies are necessary to validate their long-term success. Future studies must focus on the effectiveness of newly developed procedures, as well as defining the ideal surgical candidate. Physical therapists have the opportunity to play a substantial role in the evolution of arthroscopic hip procedures. Rehabilitation protocols, as with the surgical procedures, are still new in the field of orthopaedics, and are constantly evolving. The development of effective evidence-based rehabilitation guidelines may prove to be a crucial factor in the success of surgical procedures to address acetabular labral tears and associated pathologies.

## REFERENCES

- Alford JW, Cole BJ. Cartilage restoration, part 2: techniques, outcomes, and future directions. *Am J Sports Med.* 2005;33:443-460.
- Anderson MW, Greenspan A. Stress fractures. *Radiology.* 1996;199:1-12.
- Anderson K, Strickland SM, Warren R. Hip and groin injuries in athletes. *Am J Sports Med.* 2001;29:521-533.
- Beck M, Kallhor M, Leunig M, Ganz R. Hip morphology influences the pattern of damage to the acetabular cartilage: femoroacetabular impingement as a cause of early osteoarthritis of the hip. *J Bone Joint Surg Br.* 2005;87:1012-1018.
- Beck M, Leunig M, Parvizi J, Boutier V, Wyss D, Ganz R. Anterior femoroacetabular impingement: part II. Mid-term results of surgical treatment. *Clin Orthop Relat Res.* 2004;67-73.
- Byrd JW. Complications associated with hip arthroscopy. In: Byrd JW, ed. *Operative Hip Arthroscopy.* New York, NY: Thieme; 1998:171-176.
- Byrd JW. Hip arthroscopy utilizing the supine position. *Arthroscopy.* 1994;10:275-280.
- Byrd JW, Jones KS. Prospective analysis of hip arthroscopy with 2-year follow-up. *Arthroscopy.* 2000;16:578-587.
- Canale ST. *Campbell's Operative Orthopaedics.* 9th ed. New York, NY: Mosby; 1998.
- Cantu R. Soft tissue healing considerations after surgery. In: Maxey LM, ed. *Rehabilitation for the Postsurgical Orthopedic Patient.* St Louis, MO: Mosby; 2001.
- Clarke MT, Arora A, Villar RN. Hip arthroscopy: complications in 1054 cases. *Clin Orthop Relat Res.* 2003;84-88.
- Dvorak M, Duncan CP, Day B. Arthroscopic anatomy of the hip. *Arthroscopy.* 1990;6:264-273.
- Farjo LA, Glick JM, Sampson TG. Hip arthroscopy for acetabular labral tears. *Arthroscopy.* 1999;15:132-137.
- Ferguson SJ, Bryant JT, Ganz R, Ito K. The acetabular labrum seal: a poroelastic finite element model. *Clin Biomech (Bristol, Avon).* 2000;15:463-468.
- Ferguson SJ, Bryant JT, Ganz R, Ito K. An in vitro investigation of the acetabular labral seal in hip joint mechanics. *J Biomech.* 2003;36:171-178.
- Ferguson SJ, Bryant JT, Ganz R, Ito K. The influence of the acetabular labrum on hip joint cartilage consolidation: a poroelastic finite element model. *J Biomech.* 2000;33:953-960.
- Fitzgerald RH, Jr. Acetabular labrum tears. Diagnosis and treatment. *Clin Orthop Relat Res.* 1995;60-68.
- Funke EL, Munzinger U. Complications in hip arthroscopy. *Arthroscopy.* 1996;12:156-159.
- Ganz R, Gill TJ, Gautier E, Ganz K, Krugel N, Berlemann U. Surgical dislocation of the adult hip a technique with full access to the femoral head and acetabulum without the risk of avascular necrosis. *J Bone Joint Surg Br.* 2001;83:1119-1124.
- Ganz R, Parvizi J, Beck M, Leunig M, Notzli H, Siebenrock KA. Femoroacetabular impingement: a cause for osteoarthritis of the hip. *Clin Orthop Relat Res.* 2003;112-120.
- Glick JM, Sampson TG, Gordon RB, Behr JT, Schmidt E. Hip arthroscopy by the lateral approach. *Arthroscopy.* 1987;3:4-12.
- Griffin DR, Villar RN. Complications of arthroscopy of the hip. *J Bone Joint Surg Br.* 1999;81:604-606.
- Griffin KM, Henry CO, Byrd JWT. Rehabilitation after hip arthroscopy. *J Sport Rehabil.* 2000;9:77-88.
- Hase T, Ueo T. Acetabular labral tear: arthroscopic diagnosis and treatment. *Arthroscopy.* 1999;15:138-141.
- Hoeksma HL, Dekker J, Runday HK, et al. Comparison of manual therapy and exercise therapy in osteoarthritis of the hip: a randomized clinical trial. *Arthritis Rheum.* 2004;51:722-729.
- Ito K, Minka MA, 2nd, Leunig M, Werlen S, Ganz R. Femoroacetabular impingement and the cam-effect. A MRI-based quantitative anatomical study of the femoral head-neck offset. *J Bone Joint Surg Br.* 2001;83:171-176.
- Jobe FW, Glousman RE. Anterior capsulolabral reconstruction. In: Paulos LE, Tibone JE, eds. *Operative Technique in Shoulder Surgery.* Gaithersburg, MD: Aspen Publishing; 1992.
- Kelly BT, Weiland DE, Schenker ML, Philippon MJ. Arthroscopic labral repair in the hip: surgical technique and review of the literature. *Arthroscopy.* 2005;21:1496-1504.
- Kelly BT, Williams RJ, 3rd, Philippon MJ. Hip arthroscopy: current indications, treatment options, and management issues. *Am J Sports Med.* 2003;31:1020-1037.
- Kim SJ, Choi NH, Kim HJ. Operative hip arthroscopy. *Clin Orthop Relat Res.* 1998;156-165.
- Lage LA, Patel JV, Villar RN. The acetabular labral tear: an arthroscopic classification. *Arthroscopy.* 1996;12:269-272.
- Lavigne M, Parvizi J, Beck M, Siebenrock KA, Ganz R, Leunig M. Anterior femoroacetabular impingement: part I. Techniques of joint preserving surgery. *Clin Orthop Relat Res.* 2004;61-66.
- Leunig M. [waiting for au reply]. *Third Symposium on Joint Preserving and Minimally Invasive Surgery of the Hip.* Montreal, Canada: 2004.
- Leunig M, Werlen S, Ungersbock A, Ito K, Ganz R. Evaluation of the acetabular labrum by MR arthrography. *J Bone Joint Surg Br.* 1997;79:230-234.

35. McCarthy J, Noble P, Aluisio FV, Schuck M, Wright J, Lee JA. Anatomy, pathologic features, and treatment of acetabular labral tears. *Clin Orthop Relat Res.* 2003;38-47.
36. McCarthy JC, Noble PC, Schuck MR, Wright J, Lee J. The Otto E. Aufranc Award: The role of labral lesions to development of early degenerative hip disease. *Clin Orthop Relat Res.* 2001;25-37.
37. Mintz DN, Hooper T, Connell D, Buly R, Padgett DE, Potter HG. Magnetic resonance imaging of the hip: detection of labral and chondral abnormalities using noncontrast imaging. *Arthroscopy.* 2005;21:385-393.
38. Murphy S, Tannast M, Kim YJ, Buly R, Millis MB. Debridement of the adult hip for femoroacetabular impingement: indications and preliminary clinical results. *Clin Orthop Relat Res.* 2004;178-181.
39. Murphy SB, Barsoum W. Preliminary clinical results of ceramic-ceramic bearings in total hip arthroplasty. *Orthop J Harv Med Sch.* 2001;3:92-94.
40. Narvani AA, Tsiridis E, Tai CC, Thomas P. Acetabular labrum and its tears. *Br J Sports Med.* 2003;37:207-211.
41. Notzli HP, Wyss TF, Stoecklin CH, Schmid MR, Treiber K, Hodler J. The contour of the femoral head-neck junction as a predictor for the risk of anterior impingement. *J Bone Joint Surg Br.* 2002;84:556-560.
42. O'Leary J A, Berend K, Vail TP. The relationship between diagnosis and outcome in arthroscopy of the hip. *Arthroscopy.* 2001;17:181-188.
43. Philippon MJ. Debridement of acetabular tears with associated thermal capsulorrhaphy. *Oper Tech Sports Med.* 2002;10:215-218.
44. Philippon MJ. The role of arthroscopic thermal capsulorrhaphy in the hip. *Clin Sports Med.* 2001;20:817-829.
45. Philippon MJ, Schenker ML. Hip arthroscopy for the treatment of femoroacetabular impingement in the athlete. *Clin Sports Med.* In press.
46. Philippon MJ, Schenker ML. A new method for acetabular rim trimming and labral repair. *Clin Sports Med.* 2006;25:293-297, ix.
47. Potter BK, Freedman BA, Andersen RC, Bojescul JA, Kuklo TR, Murphy KP. Correlation of Short Form-36 and disability status with outcomes of arthroscopic acetabular labral debridement. *Am J Sports Med.* 2005;33:864-870.
48. Reynolds D, Lucas J, Klaue K. Retroversion of the acetabulum. A cause of hip pain. *J Bone Joint Surg Br.* 1999;81:281-288.
49. Rydell N. Forces acting on the femoral head-prosthesis: a study on strain gauge supplied prostheses in living persons. *Acta Orthop Scand.* 1966;37(Suppl 88):1-132.
50. Sampson TG. Complications of hip arthroscopy. *Clin Sports Med.* 2001;20:831-835.
51. Santori N, Villar RN. Acetabular labral tears: result of arthroscopic partial limbectomy. *Arthroscopy.* 2000;16:11-15.
52. Schenker ML, Philippon MJ. The role of flexible radiofrequency energy probes in hip arthroscopy. *Tech Orthop.* 2005;20:37-44.
53. Schulz KF, Chalmers I, Hayes RJ, Altman DG. Empirical evidence of bias. Dimensions of methodological quality associated with estimates of treatment effects in controlled trials. *JAMA.* 1995;273:408-412.
54. Sherman OH, Fox JM, Snyder SJ, et al. Arthroscopy—"no-problem surgery". An analysis of complications in two thousand six hundred and forty cases. *J Bone Joint Surg Am.* 1986;68:256-265.
55. Small NC. Complications in arthroscopic surgery performed by experienced arthroscopists. *Arthroscopy.* 1988;4:215-221.
56. Steadman JR, Briggs KK, Rodrigo JJ, Kocher MS, Gill TJ, Rodkey WG. Outcomes of microfracture for traumatic chondral defects of the knee: average 11-year follow-up. *Arthroscopy.* 2003;19:477-484.
57. Tanzer M, Noiseux N. Osseous abnormalities and early osteoarthritis: the role of hip impingement. *Clin Orthop Relat Res.* 2004;170-177.
58. Weber SC, Abrams JS, Nottage WM. Complications associated with arthroscopic shoulder surgery. *Arthroscopy.* 2002;18:88-95.
59. Wegener ST, Belza BL, Gall EP. *Clinical Care in Rheumatic Diseases.* Atlanta, GA: American College of Rheumatology; 1996.